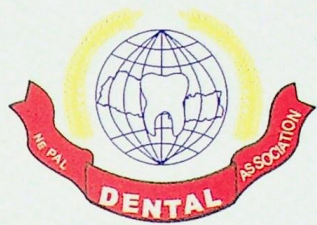


This Journal is an open access journal and
can be accessed in www.jnda.com.np

ISSN 2091-0142

Vol. 14, No. 2, Aug-Dec, 2014



JNDA

Journal of
Nepal Dental Association

Table of contents

Vol 14, No 2, Aug-Dec, 2014

Original Articles

- Expression of CD1a by Langerhans cells in oral mucosa of submucous fibrosis patients and arecanut/gutkha chewers** 1-6

Rinky Nyachhyon, Sumanth Kumbargere Nagraj, Ravikiran Ongole

- Recurrent Pleomorphic Adenoma of the Parotid Gland: Treatment Outcomes and Risks of Ulterior Recurrence** 7-16

Mahendra Maharjan, Pranay R. Sakya, Zhang Fuyin

- Antimicrobial efficacy of 0.5% Iodine potassium iodide as intracanal irrigant against *Enterococcus faecalis* at apical third of canal** 17-20

Neera Joshi, Kranti Prajapati

- Measurement of proportion of lower facial height and it's significance in different age, sex and ethnicity** 21-25

Maharjan SK, Mathema SRB

- An in-vitro Evaluation of pH and Calcium Ion Release from Calcium Hydroxide Root Canal Sealers** 26-34

Kavita Verma, Vipul Srivastava, Shrish Srivastava, Shally Mahajan, Ramesh Chandra, Afreen A Nasir

- Antimicrobial Efficacy of few commercially available herbal and non herbal toothpastes against clinically isolated human cariogenic pathogens** 35-40

Dr Amitava Bora, Dr. Abhirup Goswami, Dr. Gautam Kumar Kundu, Dr. Biswajit Ghosh

- Management of infected root canals with and without intracanal medicament in conventional root canal therapy: A comparative study** 41-45

Kranti Prajapati, Neera Joshi

Case Report

- Anatomical Challenges in Endodontics – A Series of Case Reports** 46-51

Priyanka Murgai, Rahul Bansal, Meena Kumari, Navneet Kukreja

- Tunneling: A treatment modality for furcation involved teeth –A case report** 52-56

Sonika Shakya, Shaili Pradhan

- Restoring Ailing Multirooted Abutment Through Hemisection : A Case Report** 57-59

Abhinav Gupta, Gaurav Singh, Geeta Rajput

- HAND, FOOT & MOUTH DISEASE – A Case Report** 60-63

G.Sivakumar, C.Satheesh, V.Srinivas Prasad, P.R.Ganesh

- Mandibular Infected Buccal Cyst : Two Case Reports** 64-67

Ayushi Jindal, Ritu Namdev, Parul Singhal, Samir Dutta

- Management of Cutaneous Sinus Tract of Endodontic Origin : Two Case Reports** 68-71

Dr. Sunandan Mittal, Dr. Tarun Kumar, Dr. Shifali Mittal, Dr. Jyotika Sharma