

MEDICOS

NEXT...

Complimentary Copy
National Library
Harihat Bhawan


For Further inquiry please contact us at 9849667498

**A Pandemic
Success Story**

**THE LUSH
PROMISE
OF PRP
THERAPY**

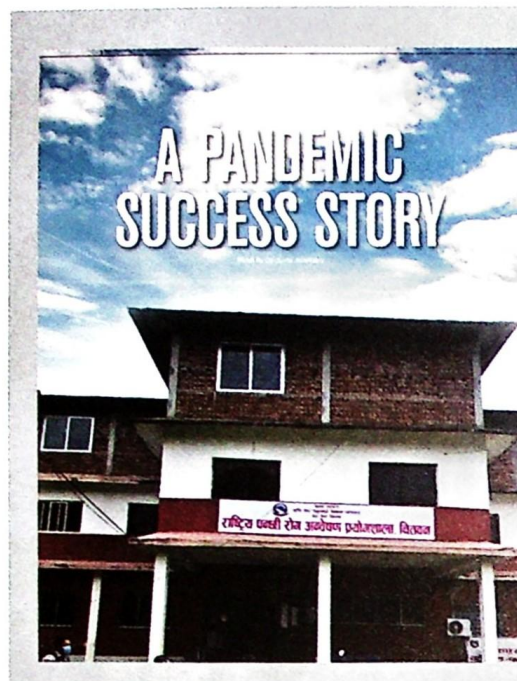
**The Quest for
Herd Immunity**

MEDICOS NEXT...



CONTENT

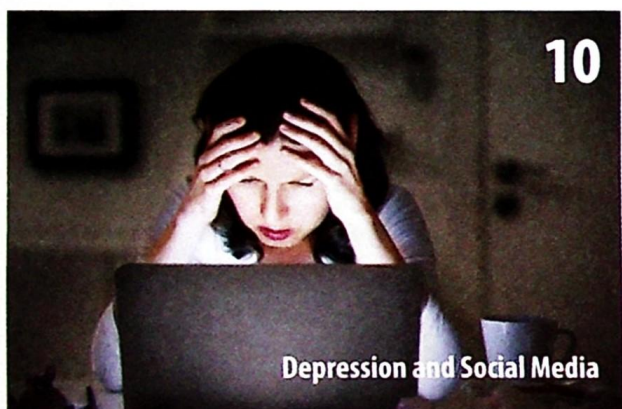
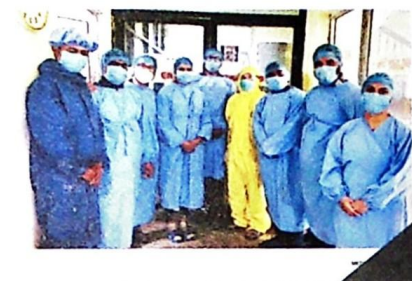FEBRUARY 2021
ISSUE 10



COVID-19 is a new disease that has affected lives worldwide. There is still a lot to learn about COVID-19 and how it has affected communities. After completing my scholarship, I was invited to the Nepal government and joined at Bhaktapur Hospital. Dr. Dipendra Chandra Thapa has brought to me the opportunity to serve as a research fellow. I am through I completed an MEd in Microbiology, which is a part of the program. I am not aware of its importance. In the past, I had been working in the government sector as a private nurse. The only good part of the COVID-19 pandemic is that it has brought about the importance of good quality laboratory services. I would be thankful to our government that BIC (Bhaktapur Hospital) has established a research center in the country.

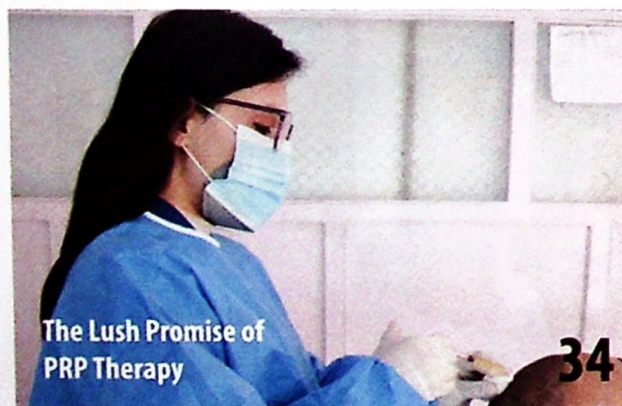laboratory was established in 1970s. Initially, the government had established a laboratory in the government sector. It was a very difficult task to establish a laboratory in the government sector. I was invited to the Nepal government and joined at Bhaktapur Hospital. Dr. Dipendra Chandra Thapa has brought to me the opportunity to serve as a research fellow. I am through I completed an MEd in Microbiology, which is a part of the program. I am not aware of its importance. In the past, I had been working in the government sector as a private nurse. The only good part of the COVID-19 pandemic is that it has brought about the importance of good quality laboratory services. I would be thankful to our government that BIC (Bhaktapur Hospital) has established a research center in the country.

of a cancer center. A 700-bed government hospital, and many private hospitals, it was a very difficult task to establish a laboratory in the government sector. I was invited to the Nepal government and joined at Bhaktapur Hospital. Dr. Dipendra Chandra Thapa has brought to me the opportunity to serve as a research fellow. I am through I completed an MEd in Microbiology, which is a part of the program. I am not aware of its importance. In the past, I had been working in the government sector as a private nurse. The only good part of the COVID-19 pandemic is that it has brought about the importance of good quality laboratory services. I would be thankful to our government that BIC (Bhaktapur Hospital) has established a research center in the country.



10

Depression and Social Media



The Lush Promise of PRP Therapy

34

IN THE NEWS

- 10 Depression and Social Media
- 12 Cheese and Wine Good for Combating Alzheimer's
- 12 New Compounds to Combat AMR
- 13 How to Stay Younger for Longer

TIMELINE

- 16 COVID-19 Vaccination

COVER STORY

- 22 The Quest for Herd Immunity

FEATURE

- 30 Excerpts from my first 100 Cases as a Cataract Surgeon
- 41 Lipid Metabolism
- 50 A Pandemic Success Story

DISEASE

- 32 Hemophilia: Bleeding Disorder with Joint damage

TREATMENT

- 34 The Lush Promise of PRP Therapy
- 38 Regaining Your Crowning Glory

WOMEN'S HEALTH

- 46 Lift Yourself Up with Cycle Syncing

TECHNOLOGY NEXT

- 54 AI Achieves Giant Breakthrough in Predicting how Proteins Fold

PHARMA

- 63 Increasing Number of Adverse Events after COVID-19 Vaccination

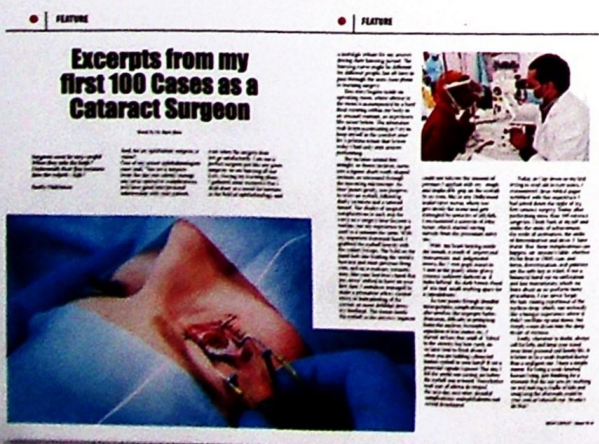PHARMA WATCH

GUIDELINES

INTERVIEW

- 26 "I think Nepal handled the pandemic relatively well," says Dr. Digbijay Raja Mahara
- 66 'Thinking Globally, Acting Locally' to Make Cancer Drugs Available in Nepal

COVID-19 IN NEPAL



Excerpts from my first 100 Cases as a Cataract Surgeon

As a cataract surgeon, I have performed over 100 cases. The first case was a 65-year-old male patient with a long-standing history of diabetes. He presented with a gradual onset of blurred vision in his right eye. After a thorough examination, I diagnosed him with a mature cataract. I performed a phacolytic cataract extraction using a manual technique. The patient's vision improved significantly post-surgery.



The second case was a 72-year-old female patient with a long-standing history of hypertension. She presented with a gradual onset of blurred vision in both eyes. After a thorough examination, I diagnosed her with bilateral cataracts. I performed a phacolytic cataract extraction using a manual technique. The patient's vision improved significantly post-surgery.